

Case report

Modified Woodward Procedure for Sprengel's Deformity with Omovertebral Extension into the Spinal Canal in an 8-Year-Old Child

Abdalsalam Andisha*^{ID}, Taimaa Langhi^{ID}

Department of Orthopaedic Surgery, Al Muwasat Hospital, Tripoli, Libya

Corresponding Email. andishaortho@gmail.com

Abstract

Sprengel's deformity is a rare congenital anomaly characterized by failure of normal scapular descent during embryologic development. It is frequently associated with omovertebral connections and may result in significant cosmetic deformity and functional limitation. Surgical treatment is indicated for moderate-to-severe cases to improve shoulder function and symmetry. An 8-year-old child presented with congenital elevation of the scapula associated with marked shoulder asymmetry and restricted abduction. Imaging demonstrated Sprengel's deformity with an omovertebral bone extending toward the spinal canal, without neurological deficit. Preoperative evaluation was performed to define the anatomy and guide surgical planning. Sprengel's deformity with omovertebral extension into the spinal canal represents a complex variant that requires meticulous surgical dissection to avoid neurovascular injury. The modified Woodward procedure provides a muscle-sparing technique that allows controlled inferior translation of the scapula with reduced risk of brachial plexus traction. Adjunct procedures, such as clavicular modification, may further facilitate scapular mobilization in rigid deformities, particularly in older children. The modified Woodward procedure is a safe and effective technique for managing Sprengel's deformity, even in complex cases with omovertebral extension. Careful preoperative imaging and precise surgical technique are essential to achieve optimal functional and cosmetic outcomes.

Keywords. Sprengel's Deformity, Woodward Procedure, Omovertebral Bone, Intraspinous Extension.

Introduction

Sprengel's deformity, or congenital elevation of the scapula, is a rare developmental anomaly characterized by failure of normal caudal migration of the scapula during embryologic development. It was first described by Eulenburg in 1863 and later comprehensively detailed by Sprengel in 1891, and it remains the most common congenital malformation of the shoulder girdle [1,2]. During normal embryogenesis, the scapula forms in the cervical region and migrates caudally to its thoracic position. Failure of this process results in a persistently elevated, hypoplastic, and often malrotated scapula. This developmental arrest is frequently associated with other congenital anomalies, reflecting a broader disturbance in embryologic patterning. The subclavian artery supply disruption sequence has been proposed as a possible mechanism, suggesting that transient vascular insufficiency during early limb development may contribute to abnormal scapular and musculoskeletal formation [6]. A characteristic feature of Sprengel's deformity is the presence of an omovertebral connection, which may be fibrous, cartilaginous, or ossified, and may link the superomedial scapula to the cervical spine. This structure contributes significantly to the restriction of scapulothoracic motion and impaired shoulder elevation [7].

Clinically, patients present with cosmetic shoulder asymmetry and variable restriction of abduction. The severity of deformity is commonly graded using the Cavendish classification system, which correlates with functional and cosmetic impairment [3]. Surgical correction is generally recommended in moderate to severe cases, particularly when functional limitation is present. Optimal timing is typically between 3 and 8 years of age, when soft tissue flexibility allows safer scapular mobilization and reduces the risk of neurovascular injury during descent [8]. This case is presented due to the rare finding of an omovertebral bone with extension toward the spinal canal, a presentation that has been infrequently reported in the literature. We describe the surgical management of this complex variant using a modified Woodward procedure, highlighting technical considerations and the feasibility of achieving satisfactory functional and cosmetic outcomes.

Case Report

An 8-year-old male patient presented with a history of left shoulder asymmetry, characterized by elevation of the left shoulder, restricted range of motion, and cosmetic concern. The patient also reported decreased shoulder abduction and mild exertional shortness of breath before surgical intervention. There was no relevant family history of similar deformities or other congenital anomalies. Antenatal history revealed that the mother had diet-controlled diabetes mellitus, with no history of medication use, radiation exposure, or other teratogenic exposures during pregnancy. The patient was born at term with a birth weight of 3200g. The patient had a solitary functioning kidney and remains under regular follow-up with nephrology services. On physical examination, there was marked elevation of the left scapula consistent with severe Sprengel's deformity, classified as Cavendish grade IV.

The deformity was associated with significant restriction of shoulder abduction, limited to approximately 50 degrees preoperatively (Figures 1 and 2).

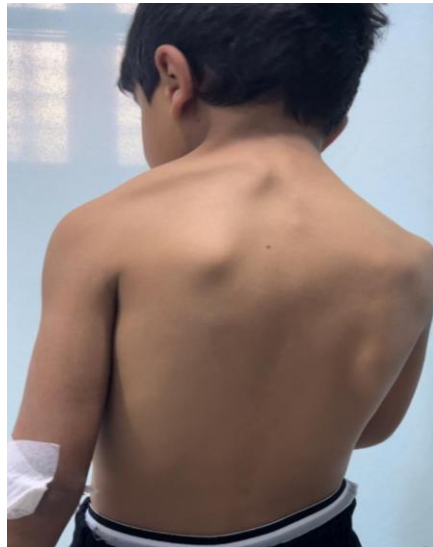

Figure 1. Preoperative clinical photograph demonstrating marked elevation of the left scapula with shoulder asymmetry consistent with severe Sprengel's deformity (Cavendish grade IV).

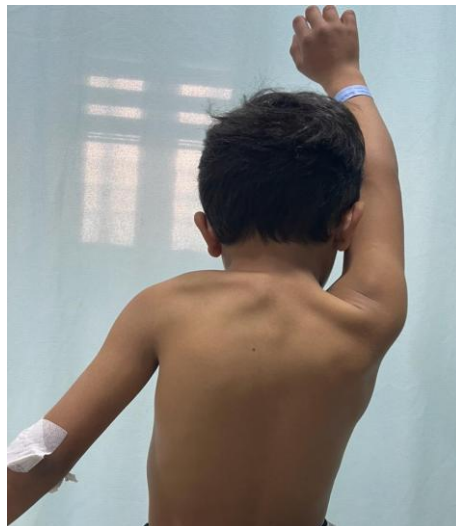

Figure 2. Preoperative clinical assessment showed restricted shoulder abduction on the affected side, limited to approximately 50 degrees.

No neurological deficits were identified, and motor and sensory examinations of the affected upper limb were normal. Computed tomography (CT) and magnetic resonance imaging (MRI) were obtained for detailed evaluation. CT imaging demonstrated an ossified omovertebral bar extending from the superomedial border of the scapula toward the cervical spine. The omovertebral connection was fully ossified. Notably, the medial end of the omovertebral bar extended into the spinal canal at the C4–C5 level, corresponding to Rigault type II (Figure 3). MRI revealed a normal-appearing cervical spinal cord at this level, with no evidence of intramedullary signal abnormality.

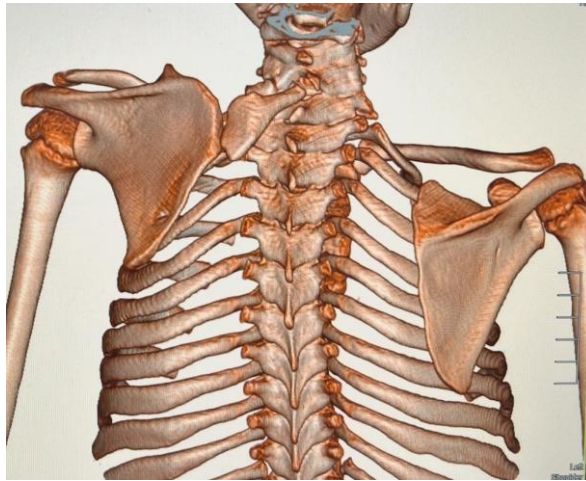


Figure 3. Preoperative CT imaging demonstrate an ossified omovertebral bone extending from the superomedial border of the scapula toward the cervical spine at the C4–C5 level, with extension toward the spinal canal.

A modified Woodward procedure was performed using a two-stage approach under general anesthesia. Initially, the patient was positioned supine, and a limited anterior approach was undertaken through a 3 cm incision over the clavicular region. Clavicular morcellization was performed to improve shoulder girdle mobility and reduce the risk of brachial plexus injury. The patient was then repositioned into the prone position. A longitudinal midline incision was made, extending from the upper cervical spine to the lower thoracic region. The lateral border of the trapezius muscle was identified at the inferior aspect of the wound. Blunt finger dissection was used to carefully separate the trapezius from the underlying thoracolumbar fascia and latissimus dorsi. Detachment of the trapezius was initiated distally and extended proximally up to the level of the fourth cervical vertebra. The muscle was then reflected laterally to expose the deeper layers. Subsequently, the rhomboid muscles were identified and similarly mobilized. Blunt dissection was used to separate them from the underlying deep fascia. Extraperiosteal dissection was performed to expose the omovertebra, which was then carefully isolated and excised.

An extraperiosteal dissection of the superomedial scapular border was performed, followed by partial resection of the prominent segment. The scapula was then gently everted and mobilized inferiorly. The latissimus dorsi muscle was elevated to allow passage and repositioning of the scapula beneath it. Inferior traction was applied to the rhomboid and trapezius muscles, allowing controlled scapular descent to the desired level. The scapular spine was positioned at the level of the contralateral side. Reconstruction of the muscular envelope was then performed. The rhomboid and trapezius muscles were reattached to the spinous processes at a more caudal level. Finally, the latissimus dorsi muscle was reattached to the scapular tip, and layered wound closure was performed. At 6 weeks postoperatively, the patient demonstrated full shoulder range of motion with marked cosmetic improvement. Muscle strength was graded 5/5, and no sensory deficits were identified in the affected upper limb (Figure 4).

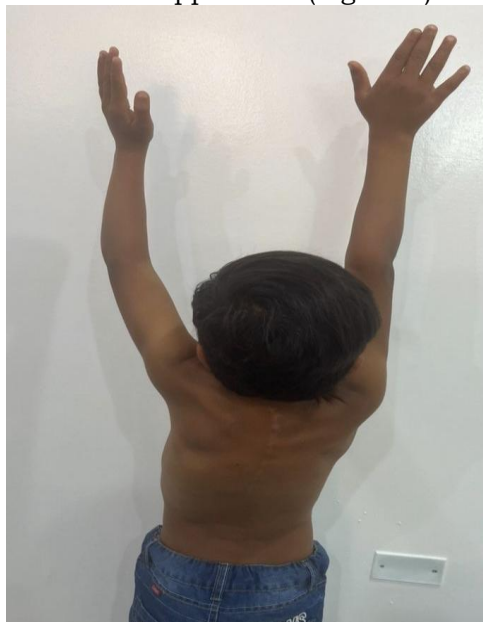

Figure 4. Six-week postoperative clinical photograph demonstrating improved scapular position, restoration of shoulder symmetry, and marked improvement in shoulder abduction.

At 3-year follow-up (current age: 11 years), these improvements were maintained, with sustained full shoulder range of motion and continued cosmetic satisfaction (Figure 6). Functionally, the patient and his family reported significant improvement, including resolution of previous limitations and absence of exertional shortness of breath.

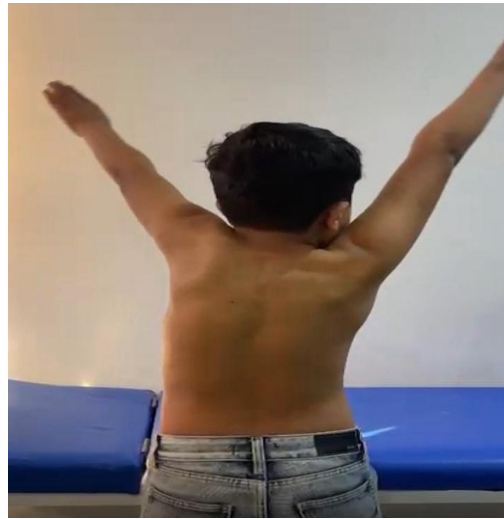

Figure 5. Three-year follow-up clinical photograph demonstrating sustained correction of scapular position with symmetrical shoulder alignment and full range of motion.

Discussion

Sprengel's deformity is a congenital condition resulting from arrested descent of the scapula during embryogenesis. Although the exact etiology remains uncertain, disruption of normal developmental migration and vascular insult during early limb formation have been implicated [6]. The subclavian artery supply disruption sequence provides a plausible explanation for the spectrum of associated musculoskeletal anomalies seen in these patients [6]. This hypothesis also accounts for the frequent coexistence of vertebral, rib, and renal anomalies in some cases. The omovertebral bone is a key anatomical feature of Sprengel's deformity and is present in a significant proportion of patients. It may be fibrous, cartilaginous, or ossified and forms an abnormal connection between the scapula and cervical spine, thereby restricting scapular rotation and contributing to functional limitation [7].

Preoperative imaging, particularly CT and MRI, is essential for defining scapular morphology, identifying omovertebral structures, and excluding associated spinal abnormalities. This is especially important in complex cases where the bony bar may extend toward the cervical canal. Surgical management is indicated in moderate to severe deformities, particularly Cavendish grade III and IV cases, where both functional limitation and cosmetic deformity are significant [3]. Several surgical techniques have been described; however, the Woodward procedure remains one of the most widely used due to its muscle-preserving approach and ability to achieve gradual scapular descent with reduced risk of brachial plexus traction injury [4,5]. The Woodward technique involves subperiosteal detachment and distal reattachment of the periscapular muscles, allowing controlled inferior repositioning of the scapula without excessive neurovascular tension [4].

Timing of surgery is a critical factor influencing outcomes. Most authors recommend intervention in early childhood, typically between 3 and 8 years of age, when soft tissues are more adaptable and scapular mobility is greater [8]. In older children and adolescents, increased soft tissue stiffness and the greater required distance of scapular descent increase surgical complexity and theoretical risk of neurovascular stretch injury. Despite these challenges, the present case demonstrates that satisfactory functional and cosmetic outcomes can still be achieved in late-presenting patients when meticulous soft tissue release and controlled scapular mobilization are performed. Adjunct procedures, such as clavicular modification, may further facilitate scapular descent in rigid deformities. Long-term studies have shown that the Woodward procedure provides durable correction with low recurrence rates and sustained functional improvement when adequate muscular reattachment is achieved [5,9,10].

Conclusion

Sprengel's deformity is a rare congenital anomaly that may present with significant cosmetic and functional impairment, particularly in moderate to severe cases associated with omovertebral connections. Although the optimal age for surgical correction is early childhood, this case demonstrates that acceptable functional and cosmetic outcomes can still be achieved in older children when meticulous soft tissue release and controlled scapular mobilization are performed. The modified Woodward procedure remains a reliable and muscle-sparing technique that allows gradual inferior translation of the scapula while minimizing the risk

of brachial plexus traction injury. The presence of an omovertebral extension, even when extending toward the spinal canal, necessitates careful preoperative imaging and precise intraoperative dissection to ensure safe excision and adequate decompression. Adjunct maneuvers, including clavicular modification and structured periscapular muscle reattachment, may further facilitate scapular descent in rigid deformities. Overall, this case supports the effectiveness of the modified Woodward procedure as a safe and reproducible option for complex Sprengel's deformity, even in late-presenting patients with challenging anatomy.

Informed Consent

Informed consent was obtained from the patient's legal guardians for publication of this case report and any accompanying images.

Ethical Approval

Ethical approval was not required for this case report, in accordance with institutional policies.

Author Contributions

Dr. Abdalsalam Andisha: Conception and design of the study, case data collection, clinical interpretation, and critical revision of the manuscript. Dr. Taimaa Langhi: Manuscript writing, figure preparation, and critical revision of the manuscript. Both authors: Conducted literature review, contributed to analysis and interpretation of findings, and approved the final manuscript.

Funding

This study received no external funding.

Conflicts of Interest

The authors declare no conflicts of interest related to this study.

Guarantor

Dr. Abdalsalam Andisha is the guarantor of this work and accepts full responsibility for the integrity of the case report and its contents.

References

1. Eulenburg A. Beitrag zur angeborenen Elevation des Schulterblattes. *Virchows Arch Pathol Anat.* 1863;28:111-125.
2. Sprengel O. Die angeborene Verschiebung des Schulterblattes nach oben. *Arch Klin Chir.* 1891;42:545-574.
3. Cavendish ME. Congenital elevation of the scapula. *J Bone Joint Surg Br.* 1972 Aug;54(3):395-408.
4. Woodward JW. Congenital elevation of the scapula: correction by release and transplantation of muscle origins. *J Bone Joint Surg Am.* 1961 Apr;43-A:219-228.
5. Carson WG, Lovell WW, Whitesides TE Jr. Congenital elevation of the scapula: surgical correction by the Woodward procedure. *J Bone Joint Surg Am.* 1981 Oct;63(8):1199-1207.
6. Bavinck JN, Weaver DD. Subclavian artery supply disruption sequence: hypothesis of a vascular etiology for Poland, Klippel-Feil, and Möbius anomalies. *Am J Med Genet.* 1986 Apr;23(4):903-918.
7. Cho TJ, Choi IH, Chung CY, Hwang JK. The Sprengel deformity: morphometric analysis using 3D CT. *J Bone Joint Surg Br.* 2000 Jul;82(5):711-718.
8. Khair MM, Hoffer MM. Surgical management of Sprengel's deformity: systematic review. *J Pediatr Orthop B.* 2014 Jul;23(4):300-306.
9. Gonen E, Gonen B, Onay VM, Kaygusuz MA. Long-term results of modified Woodward procedure for Sprengel deformity. *J Shoulder Elbow Surg.* 2015 Aug;24(8):1261-1267.
10. Li Y, Yu J, Wu Z, Wang S, Shao J, Zhao D. Modified Woodward procedure for Sprengel deformity: mid-term outcomes. *Orthop Surg.* 2020 Oct;12(5):1453-1460.